



PATIENT

BamBam Cummings

SPECIES

Canine

BREED

Chihuahua

SEX

Male Neutered

AGE

15 Years

WEIGHT

8 lbs.

INTERPRETED BY

Andrea Nicastro, DVM,
Diplomate ACVIM
(Small Animal Internal
Medicine)

**IMAGING
PERFORMED BY**

Kelly Reshny, RVT

HOSPITAL NAME

Sixteen Mile VC

REFERRING VET

Dr. Gibbs

INVOICE

11749kk

DATE

9/3/21

PRESENTING CLINICAL SIGNS

History: Very poor appetite, failure to thrive.

Abnormal PE/Chem/CBC/UA Results: Mildly elevated BUN and ALT. Thrombocytosis. Specific gravity is 1.040. No proteinuria. Inactive sediment.

ULTRASONOGRAPHIC EXAMINATION OF THE ABDOMEN

Urinary System

The urinary bladder, trigone, and pelvic urethra are normal in thickness and the mucosal surface is smooth. The bladder lumen is moderately distended with mostly anechoic urine. No masses, inflammatory changes or calculi are observed. Ureteral papillae and visualized portion of the proximal urethra, visible to a depth of 2 cm, are normal.

The prostate is normal in size (0.94 cm in width) and shape. Parenchyma is homogenous. The prostatic urethra appears normal without evidence of dilation or obstruction.

The left kidney is normal size (3.32 cm in length); normal shape and architecture with smooth peripheral margins. There is a normal 1:3 cortex to medulla ratio with minimal loss of corticomedullary distinction. There is no evidence of pyelectasia, nephroliths, infarcts or hydronephrosis. Renal vasculature is normal.

The right kidney is normal size (3.75 cm in length); normal shape and architecture with smooth peripheral margins. There is a normal 1:3 cortex to medulla ratio with minimal loss of corticomedullary distinction. There is no evidence of pyelectasia, nephroliths, infarcts or hydronephrosis. Renal vasculature is normal.

Adrenal Glands

The left adrenal gland is normal size (0.53 cm at cranial pole) (0.52 cm at caudal pole) (1.62 cm in length); normal shape; homogenous parenchyma. The glandular echogenicity and detail are unremarkable. Capsule, cortex, and medullary definition are normal. The phrenicoabdominal vein and surrounding vasculature are normal.

The right adrenal gland is normal size (1.27 cm at cranial pole) (0.45 cm at caudal pole) (1.81 cm in length); normal shape; homogenous parenchyma. The glandular echogenicity and detail are unremarkable. Capsule, cortex, and medullary definition are normal. The phrenicoabdominal vein and surrounding vasculature are normal.

Spleen

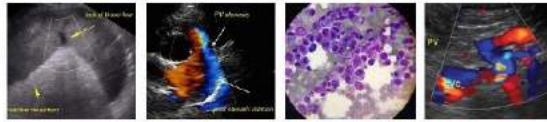
The spleen is normal in size (0.82 cm in width at the level of the hilus) with a normal capsular contour. There is appropriate echogenicity and echotexture. No focal lesions are observed. Splenic vasculature is normal.

Liver

The liver is subjectively normal in size with normal contours and structure. There is appropriate echogenicity and echotexture. No overt structural evidence of inflammatory, infiltrative, or regenerative pathology is evident. Vascular and biliary tracts are of normal volume with no evidence of congestion. No pathological hepatic lymphadenopathy observed. The gall bladder lumen is moderately distended. The wall is thin and smooth. Luminal contents are anechoic. The cystic and common bile ducts are normal/not seen.

Gastrointestinal

The stomach and intestine are free of stasis and exhibit normal peristaltic activity. The gastric lumen is minimally fluid-distended. The gastric wall and pylorus are normal in thickness with a normal layering pattern. The pyloric outflow tract is patent. The small intestinal lumen is not dilated. The small intestinal wall



PATIENT

BamBam Cummings

thickness is normal with a normal layering pattern and appropriate mural detail. Discreet masses are not identified. The colonic wall is normal. No obstructive disease is noted.

Pancreas

SPECIES

Canine

The right limb of the pancreas is visible with normal curvilinear peripheral contours. The parenchyma is largely isoechoic relative to surrounding omental fat and slightly mottled in appearance. The pancreatic duct is visible but not overtly dilated. There is no evidence of peripancreatic inflammation or effusion.

Free Abdomen

BREED

Chihuahua

The peritoneal cavity is normal. There is no evidence of inflammation or effusion. The abdominal lymph nodes are normal/not visible.

SEX

Male Neutered

ULTRASONOGRAPHIC FINDINGS

Primary Findings:

**An obvious cause for the patient's clinical signs is not identified in this study.

AGE

15 Years

Secondary Findings:

- Minor age-related renal pathology.
- The pancreatic changes are most consistent with age-related parenchymal remodeling, potentially secondary to a prior inflammatory episode, early fibrosis or chronic pancreatitis.

WEIGHT

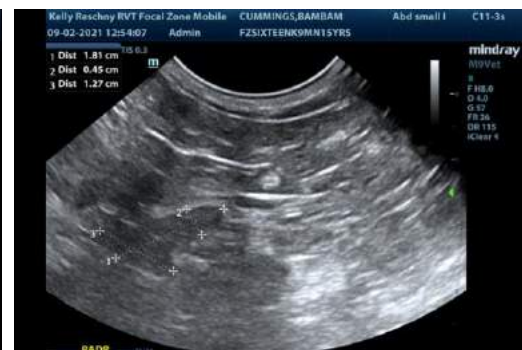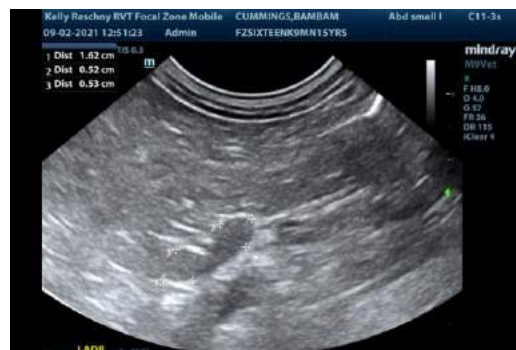8 lbs.

INTERPRETATION OF THE FINDINGS & FURTHER RECOMMENDATIONS

1. Three-view thoracic radiographs are recommended to assess for occult neoplasia.
2. Thorough orthopedic and neurologic examinations are recommended to assess for sources of pain and/or neuropathies, which may be affecting the patient's appetite.
3. A T4/free T4 by equilibrium dialysis is also recommended to complete the baseline lab work.

INTERPRETED BY

Andrea Nicastro, DVM,
Diplomate ACVIM
(Small Animal Internal
Medicine)



IMAGING PERFORMED BY

Kelly Reshny, RVT

HOSPITAL NAME

Sixteen Mile VC

REFERRING VET

Dr. Gibbs

INVOICE

11749kk

DATE

9/3/21



PATIENT

BamBam Cummings

SPECIES

Canine

BREED

Chihuahua

SEX

Male Neutered

AGE

15 Years

WEIGHT

8 lbs.

INTERPRETED BY

Andrea Nicastro, DVM,
Diplomate ACVIM
(Small Animal Internal
Medicine)

**IMAGING
PERFORMED BY**

Kelly Reshny, RVT

HOSPITAL NAME

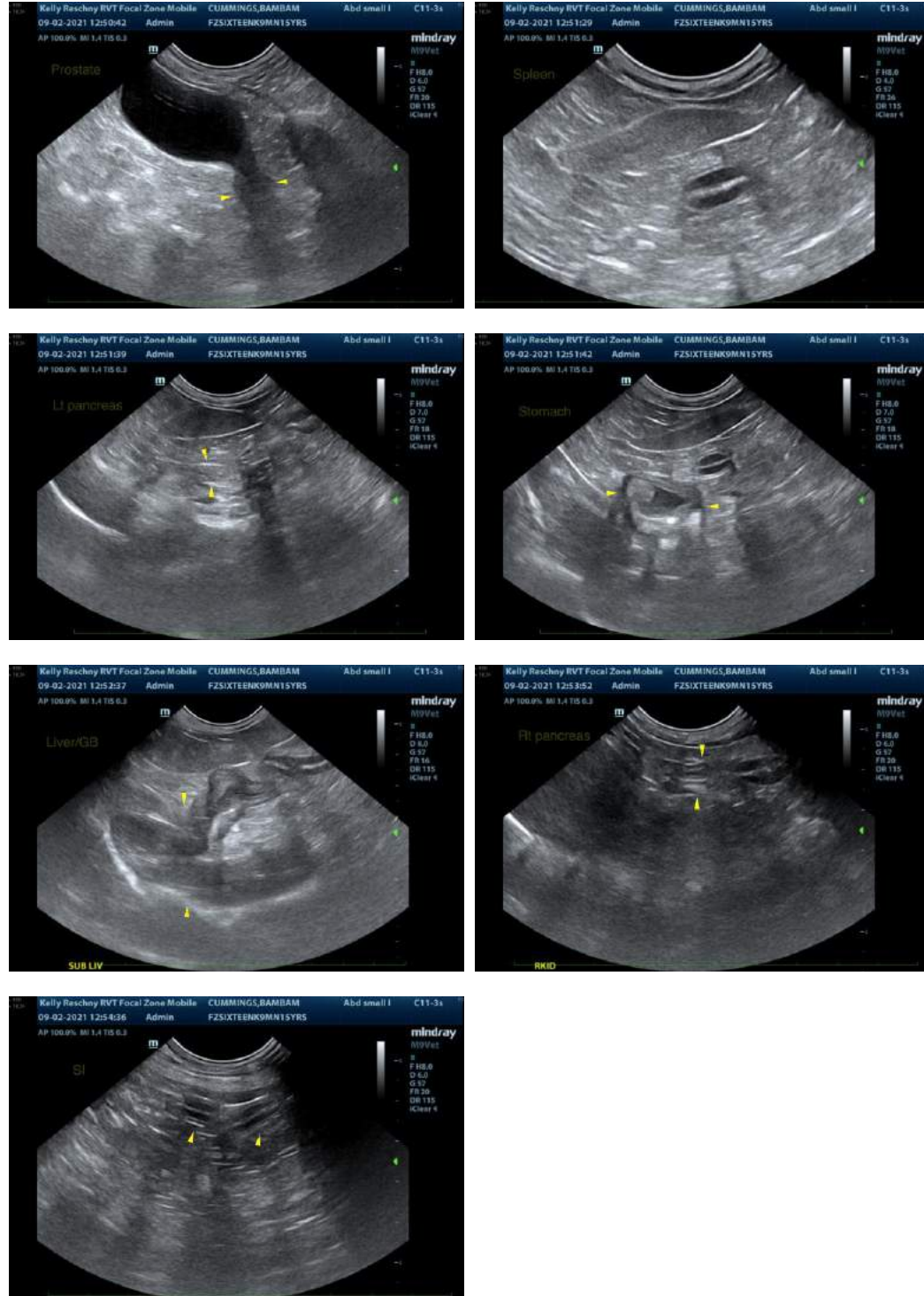
Sixteen Mile VC

REFERRING VET

Dr. Gibbs

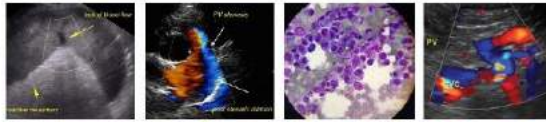
INVOICE
11749kk

DATE
9/3/21



The information and recommendations provided are based on the images presented by the referring veterinarian. No evaluation can be communicated regarding pathology that was not visible in the image/video clips provided.

Thank you for this referral. If the clinical or image interpretation does not parallel your findings or if I can be of any further assistance, please contact me.



PATIENT

BamBam Cummings

Andrea Nicastro, DVM, Diplomate ACVIM (*Small Animal Internal Medicine*)
Andrea.nicastro@sonopath.com

SPECIES

Canine

BREED

Chihuahua

SEX

Male Neutered

AGE

15 Years

WEIGHT

8 lbs.

INTERPRETED BY

Andrea Nicastro, DVM,
Diplomate ACVIM
(*Small Animal Internal
Medicine*)

**IMAGING
PERFORMED BY**

Kelly Reshny, RVT

HOSPITAL NAME

Sixteen Mile VC

REFERRING VET

Dr. Gibbs

INVOICE

11749kk

DATE

9/3/21